

LEARNING OBJECTIVES:

- Learn the clinical approach to bleeding disorders, specifically platelets disorders versus coagulation disorders
- Discuss and differentiate between extrinsic and intrinsic pathways.

Case Presentation

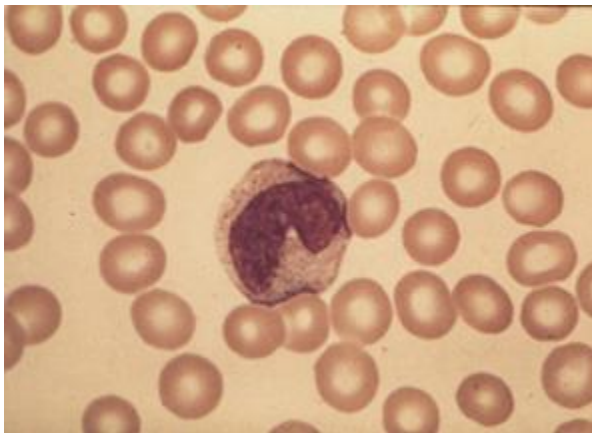
A young female of 30-years had noticed bruising on her arms and legs for 4-5 days. The bruises were not painful but were increasing in number every day. She had no fever or other evidence of infection and did not admit to taking any medications.

The examination revealed healthy looking young female with bruising and petechiae on her arms and legs. There was no other abnormality specifically the spleen was not palpable and lymph nodes were not enlarged. There was no evidence of IV drug ingestion.

Q 1 . How should the patient be managed?

The initial laboratory workup revealed

Table 1. complete blood count	
Haemoglobin (Hb)	11.2 g/dl
WBC	8000/cmm
Platelet count	18,000/cumm
Bleeding time	More than 10 minutes
Clotting time	5 minutes
Prothrombin time	15/13
Activated partial thromboplastin time	35/35



Q 2. How would you interpret the full blood count and coagulation screen?

Q 3. What advice should be given to the patient?

Q 4. Name few medicines that have been associated with thrombocytopenia?

Q 5. What further tests would be advised ?

The biochemical screen was normal and the abdominal ultrasound revealed a normal spleen size with no intra abdominal masses or lymphadenopathy.

Q6. What other serological investigations should be carried out?